

**TECHNICAL NOTE**

# Modified Pull-Out Technique for Zone One Flexor Digitorum Profundus Repair

Mohammadreza Azarpira, MD<sup>1</sup>; Ghada Asmar, MD<sup>1</sup>; Marc-Olivier Falcone, MD<sup>1,2</sup>*Research performed at Ashford and St Peter's NHS FT & Fortius Clinic, UK*

Received: 24 May 2022

Accepted: 05 July 2022

**Abstract**

Pull-out suture fixation is widely used to fix zone one flexor tendon injuries. The original technique of Bunnell generally has good results. However, in some cases, it may result in complications, including nail deformity and infection. The all-inside techniques for fixation of the tendon at this zone cannot totally replace the Pull-out technique. In this article, we propose a modification of the pull-out technique, which can reduce the complications and report the results of our patients' series.

**Level of evidence:** IV**Keywords:** Flexor tendon repair zone one, Flexor tendon injury, Jersey finger, Pull-out suture, Surgical complication**Introduction**

Zone one flexor tendon injuries are defined as Flexor Digitorum Profundus (FDP) tendon injuries distal to the Flexor Digitorum Superficialis (FDS) insertion.<sup>1</sup> The injury can be due to a laceration or a closed avulsion.

Pull-out suture and fixation of the tendon to the nail plate by using a button, popularized by Bunnell, has been the most popular technique for tendon insertion to the bone in this injury for the last 80 years.<sup>2</sup> Despite its popularity, possible cosmetic nail deformity and infection are two major drawbacks of this technique.<sup>3</sup> Several modifications were proposed for reducing these complications' risk, including positioning the knot over the fingertip using an interposition material below the button or fixation over a Kirschner wire.<sup>4,5</sup>

Although Bunnell's pull-out method is advantageous for the reattachment of tendon to bone in different clinical situations, two disadvantages of this technique are responsible for the adverse results: the first one is the transosseous tunnel and risk of osteomyelitis, and the second one is a spot of hyper-pressure over the nail bed or skin.<sup>3,5</sup>

Here we describe our pull-out technique, which is optimized to reduce complications risk. We also

present the clinical outcomes of a series of patients who underwent surgery using this technique.

**Technical note**

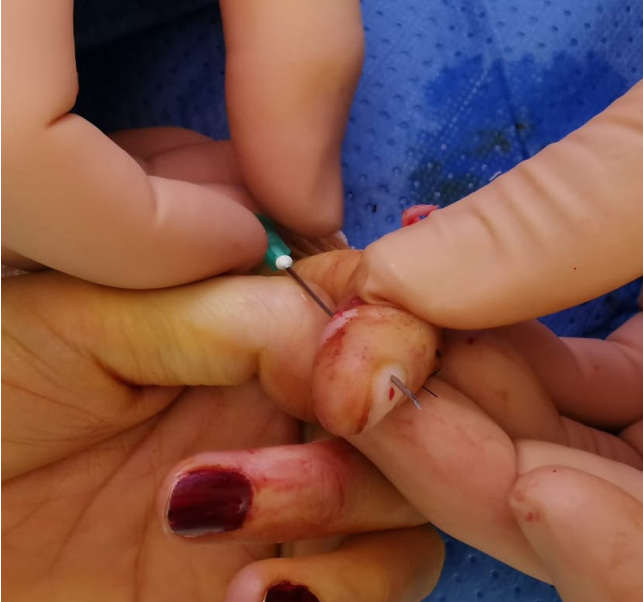Surgery is carried out under a brachial plexus block in the supine position with an arm tourniquet inflated at 250 mmHg. A volar zigzag (Bruner) skin incision over the volar skin crease of the distal interphalangeal joint (DIP) is done. Then the two neurovascular pedicles and the flexor tendons sheath are explored and dissected.

After irrigation and hematoma evacuation in acute injuries, surgical exploration and eventually retrieving of the retracted tendon to the level of the distal phalanx are performed. Two 21-gauge hypodermic needles are prepared. On one side, an antegrade first needle is passed from the tendon remnants through the lateral aspect of the distal phalanx to exit laterally through the nail plate, away from the lateral nail fold, to create a first fixing point [Figure 1]. Using this needle as a guide, another needle follows the trajectory retrogradely from the dorsal (nail plate) to the volar side [Figures 2, 3]. The end of a 2-0 nylon suture is passed through the 21-gauge needle, which is then removed. The FDP tendon is sutured using a modified Kessler technique at about 7mm from the

**Corresponding Author:** Marc-Olivier Falcone, Ramsay Générale de Santé, Capio, Hôpital Privé Paul d'Egine, Champigny-sur-Marne, France

Email: falcone.research@gmail.com

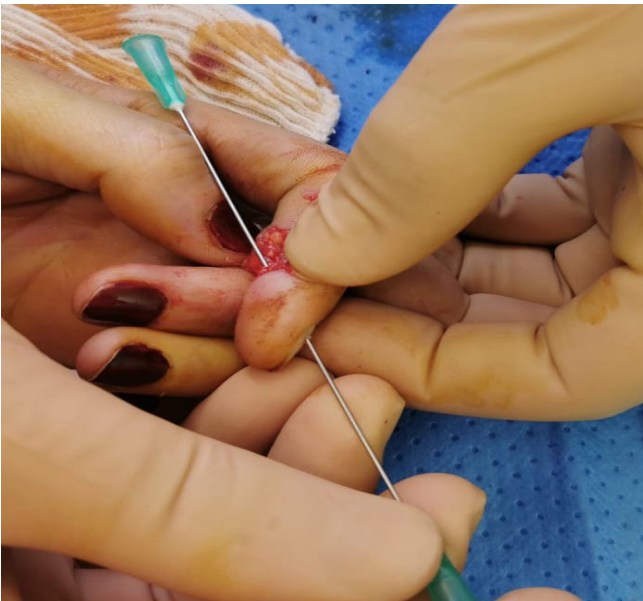THE ONLINE VERSION OF THIS ARTICLE  
ABJS.MUMS.AC.IR



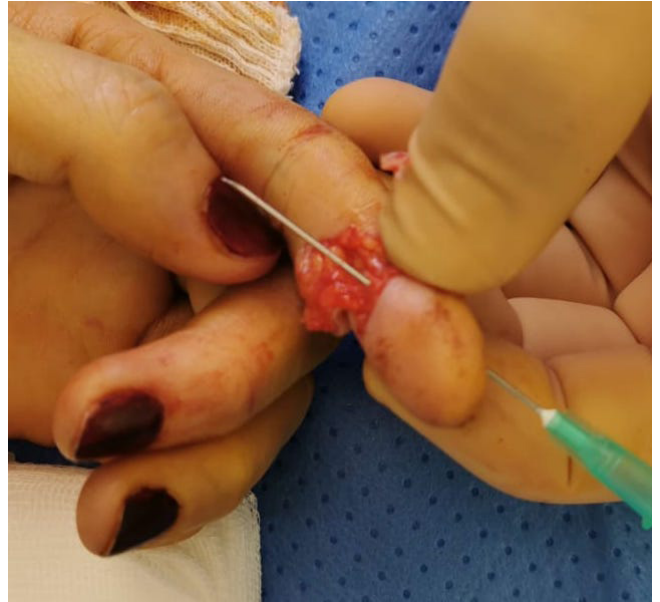**Figure 1.** Needle is passed through tendon remnants along the side of the distal phalanx and exits through the nail plate, not engaging the nail folds.

tip of the tendon, and the needle of the nylon suture is then cut. The same trajectory sequence of a 21-gauge hypodermic needle is used at the other side of the distal phalanx, and the other end of the nylon suture thread is passed through the needle from volar to dorsal, providing a second fixing point [Figure 4].

As a result, each nylon suture thread is attached to the



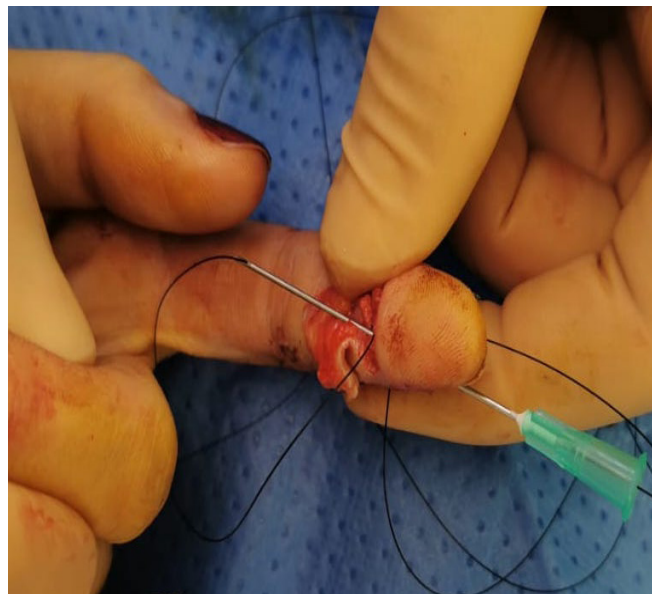
**Figure 2.** The second needle is pushed on the tip of the first needle and replaces the first needle.



**Figure 3.** Second needle in place.

tendon by a modified Kessler suture and is running at each side of the distal phalanx, piercing the nail bed and exiting from the nail plate, adjacent to but away from the lateral nail folds at the dorsum of the distal phalanx.

The nylon suture is tied over the nail plate using the appropriate size of the perforated part of a small suction drain. The nylon suture threads are passed into two separate holes at each side of the tube, and then the dorsal side of the tube is incised between these two



**Figure 4.** After making a modified Kessler suture at the tendon tip, the suture needle is cut, and the Nylon suture is passed through the second needle.

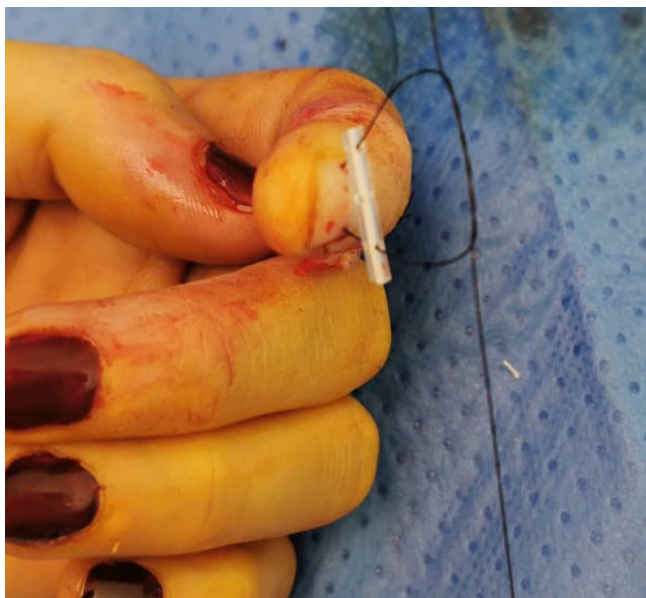

Figure 5. Passing the Nylon sutures into the plastic tube at two different holes and double non-locking knot of Nylon suture.

holes to form a gutter. Here, a non-locking double knot is made and gently tightened or released in the gutter until obtaining the optimal tendon tension [Figure 5]. The goal is to obtain a physiological digital flexion cascade when the wrist is in extension and a complete extension of the injured finger when the wrist is in flexion [Figure 6]. Once good tension is obtained, several locking knots are made, and the stability of the fixation is checked.

The volar incision is closed using non-absorbable sutures. If, after debridement of the wound borders, direct suture closure cause flexion contracture of the DIP joint, a skin advancement flap, usually Hueston type, is used for tension-free wound closure. Active-assisted finger motion protected by a splint is started within two or three days after surgery. A five-day-a-week specific rehabilitation protocol is prescribed to allow early protected active mobilization, supervised by a physiotherapist. A Duran orthosis is worn continuously for six weeks between the rehabilitation sessions. After six weeks, the pull-out suture is removed by the surgeon by cutting one side of the nylon suture at the nail plate level and pulling on the pull-out system. Unrestricted forceful activities are allowed after the third month.

#### **Clinical investigation**

In a single-center, single-operator, retrospective, observational study approved by our Institutional Review Board, the medical database of our center was searched for patients who underwent the pull-out technique between 2006 and 2020. All patients provided informed consent to participate in this study and use their de-identified health data.

The inclusion criteria were zone one flexor tendon injury, including laceration and avulsion injuries, ability to adhere to the early protected active motion protocol

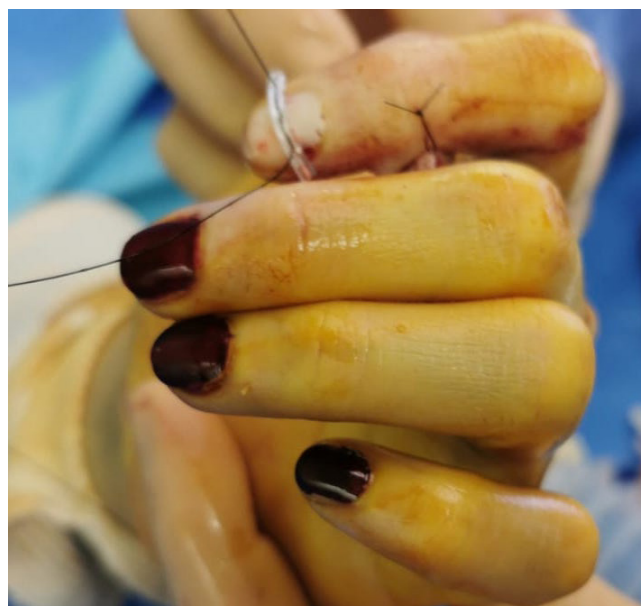


Figure 6. Tightening the knot till obtaining harmonious flexion fingers cascade.

post-operatively, and having a minimum of one year of follow-up.

The exclusion criteria were injuries preventing immediate finger motion, tendon repair or fractures of the same hand needing immobilization, replantation of the operated finger, moderate to severe crush injuries, and failure to follow the physical therapy protocol.

#### **Results**

Forty-three consecutive patients underwent surgery between 2006 and 2020 for zone one tendon injuries. All surgeries were done as urgent operations by a single senior hand surgeon with high experience, consistent with grade four of Tang et al. classification of levels of expertise.<sup>6</sup> Five patients were excluded from the study: two did not follow physical therapy protocol, two had a severe crush injury (chain of bicycle and hedge trimmer), and one sustained a concomitant FDS injury to the same finger.

The study population and injury characteristics are shown in [Table 1]. The most common associated injury was digital nerve injury. The microsurgical repair of the nerve was carried out without modifying the physical therapy protocol. Other associated injuries were a partial fracture of the distal phalanx in two cases and a superficial laceration of the other fingers of the same hand in two cases.

The patients were followed up for one year. All returned to work after three months. One patient with a jersey finger developed adhesion at the A4 pulley level, for which a surgical release was carried out later. For the other patients, the range of motion of the DIP joints at the one-year follow-up was good or excellent, according to Moiem and Elliot's classification. In this classification, the quality of results is expressed according to the range of motion of the DIP joint. Ranges of motion of DIP joints more than 51 and 62 degrees correspond to good and

Table 1. Patient population and injury characteristics	
Number of patients/fingers	38/39
Gender ratio, Female/Male	7/31
Mean age at surgery	36.7 years (17-69)
Professions (number)	Active workers (29), Students (7), Retired (2)
Mode of accident	Domestic (60%), work-related (40%)
Mechanism of injury	Laceration (90%), Jersey finger (10%)
Laterality	14 right hand (36%), 24 left hand (64%)
Injured finger of right hands	4 thumbs, 6 indexes, 2 middle fingers, 2 ring fingers, 1 little finger
Injured finger of left hands	4 thumbs, 6 indexes, 5 middle fingers, 5 ring fingers, 4 little fingers
Location of Jersey finger	3 in left ring finger and 1 in left little finger
Digital nerve injury (side)	60% of fingers (60% in ulnar side, 40% in radial side)
Degree of tendon injury	82% Complete cut, 18% Partial cut (more than 75% of FDP cross section)

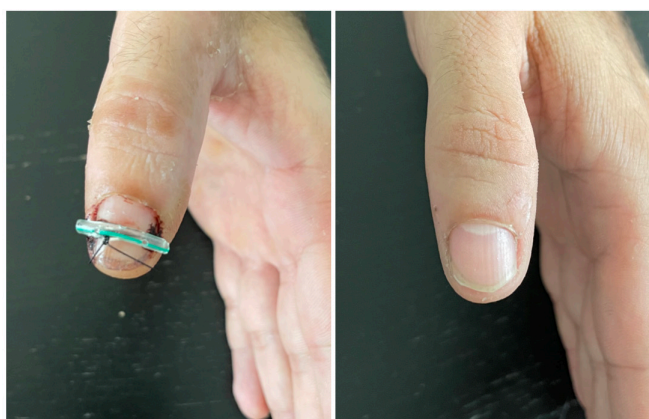

Figure 7. Three weeks after surgery of pull-out suture fixation. The same patient at nine months of follow-up with a normal nail.

excellent results, respectively.<sup>7</sup>

No nail deformities were noticed at the one-year follow-up [Figure 7]. Our criteria for nail deformity include any change in shape, contour, or size compared to the normal preoperative nail. None of the patients developed an infection. A 60-year-old mechanic worker developed a complex regional pain syndrome type 1. He developed swelling, redness, and pain in his hand with restricted finger motion. The rehabilitation protocol was continued. He improved at one year of follow-up.

## Discussion

Pull-out suture for fixation of the FDP tendon to the bone is a common technique of repair in zone 1 flexor tendon injuries.<sup>8</sup> Al-Qattan reported four cases of jersey fingers: all occurred in young men's ring fingers. A pull-out suture was done through the nail plate to fix the bone fragments and the flexor tendon. K-wire fixation of the distal phalanx was added for extra-articular fractures. He reported one nail bed deformity due to the pull-out fixation method.

All patients achieved excellent results using Strickland

grading.<sup>9</sup> In another article, McCallister et al.<sup>10</sup> reported the results of 13 cases of pull-out repair of flexor tendon injuries. The mechanism of injury was a laceration in seven patients and avulsion in six. Five patients had associated digital nerve injuries. In their technique, the two tails of the pull-out suture were passed through the lateral sides of the distal phalanx and the nail folds, and the knot was tightened over the nail plate. They reported two infections. At the final follow-up, the mean range of motion of DIP was 57.3 ± 3.8 degrees, and the mean flexion contracture of DIP was 9.5 ± 4.8 degrees. Kang et al.<sup>3</sup> reported the results of 23 pull-out procedures for zone one flexor tendon injury. The mechanism of injury was a sharp injury in 15 patients, avulsion in seven, and crush injury in one patient. All the operations were done by a "trainee surgeon on call". Fifteen patients showed complications, including eight nail deformities, no nail growth within six months in two fingers, five infections, hypersensitivity in three fingers, complex regional pain syndrome, tendon rupture, and tip amputation, each one was noted in one finger. This article discussed the impact of the surgeon's experience, careful surgical procedure, and avoiding over-tensioning of the knot. Bidwai et al.<sup>5</sup> reported 37 cases of pull-out fixation for flexor tendon injury at zone one. The mechanism of injury was a sharp cut in 19 and avulsion in 18 patients. Surgeries were performed by consultant surgeons in 11% and by trainee surgeons in 89% of patients. The mean DIP range of motion at the final follow-up was 37.5 degrees. Complications included: one tendon rupture, two tendon adhesions, two DIP severe flexion contractures (one associated with cold intolerance), one pull-out site infection, and one swan neck deformity. No cosmetic nail deformity was noted at the final follow-up.

Rigó et al. reported the results of 35 fingers with pull-out fixation of zone one FDP injury. They included four superficial infections; tendon rupture and flexion contracture of DIP or proximal interphalangeal (PIP) joints each in one patient; two granulomas; one nail deformity, and one carpal tunnel syndrome. According

to Strickland's classification, eleven fingers achieved excellent or good results.<sup>11</sup>

Tempelaere et al.<sup>12</sup> reported treatment results of 29 jersey fingers, of which 23 fingers were treated by pull-out technique (20 fingers by the pull-out alone and in three fingers the combination of pull-out and either anchor, screw, or wire). For other fingers, only internal fixation methods were used. One anchor fixation failure was revised by pull-out with excellent results. Overall, the mean final Quick DASH score was 5.66. Regarding the pull-out complications, one rupture, three nail deformities, and five arthrodeses were reported. At the final follow-up using the Buck-Gramcko classification, four excellent, six good, two moderate, and seven poor results were reported.<sup>12</sup>

In our patients, we did not notice any infection or nail deformity. This can be explained by several factors, including the minimal delay of surgery in the urgent context, careful technique performance by an expert hand surgeon, and pull-out of the suture tails passing to the side of the distal phalanx bone and then through the lateral edge of the nail plate, not through the nail folds. This technique provides an extra-osseous solid fixation point without compromising soft tissue circulation. Our technique is totally different from the fixation method of McCallister et al.<sup>10</sup>; in his technique, the tightened suture is over the entire nail plate through the nail folds. Consequently, the pull-out suture fixation pressure is acting on the paronychial soft tissue; the suture can slide proximally in the soft tissue along the edge of the nail plate, with the risk of skin ischemia and necrosis and nail dystrophy by matrix lesion or infection. However, in our technique, the nail folds are free, and the force of the pull-out suture is distributed over the surface of the solid nail plate. In addition, tightening the knot until achieving normal finger cascade in wrist extension and flexion helped avoid over-tensioning of the knot.

As mentioned earlier, several cases of nail deformity, fingertip dystrophy, or infection<sup>3</sup> after using the pull-out techniques were reported in the literature. These complications encouraged using alternative internal fixation methods, including anchors or direct sutures to the bone, known as all-inside techniques. However, these alternatives did not produce superior strength to failure.<sup>13</sup> There are also some concerns about the cost of the anchors and their fixation strength in osteoporotic patients.<sup>13,14</sup> That is one of the reasons the pull-out technique is still widely used for FDP lesions in zone one.

Polferet al. described a technique for adding a transosseous suture as a backup fixation if the anchor fixation pulls out. The suture was tied over the dorsum of the distal phalanx, proximal to the nail matrix, and over the terminal band of the extensor tendon. The tendon suture was done by 4-0 non-absorbable suture. This technique needs a dorsal counter-incision and avoids nail matrix damage. The authors mentioned that the suture knot under the thin skin of the dorsum of the distal phalanx may become problematic and may require the removal of the knot three months later.<sup>15</sup>

The fingertip fixation of the pull-out provides frequent necrosis by overpressure, requiring a long phase of directed

healing after removing the pull-out, which is often poorly tolerated. As a result, pulpal dystrophy is often observed.<sup>4</sup>

The major infectious complication of the pull-out through the nail bed is osteomyelitis of the distal phalanx.<sup>3,8</sup> In transosseous methods, the pull-out sutures go through a tunnel in the bone and the nail before fixation to the button.<sup>5,8</sup> The space between a rigid disk-shaped button and a curved nail makes a suitable environment for bacterial proliferation, while there is a direct path along the suture to the bone. Eventual pressure necrosis beneath the button can also lead to infection. Leaving the fixation button for six weeks can cause a chronic finger infection and permanent sequelae.<sup>3</sup> With our technique, there is no tunnel into the bone, and the risk of osteomyelitis is minimized.

Another complication is nail deformity after the pull-out technique. This is due to possible damage of the sterile or germinal matrix while drilling the distal phalanx, hyperpressure and soft tissue necrosis beneath the fixation button, or eventual infection.<sup>3,11</sup> The techniques that use a single passage of the pull-out suture concentrate the entire pull tension of the tendon over a single point on the nail or skin. In our technique, the two threads of the suture go from each side of the distal phalanx and through the most lateral side of the nail bed, and the nail plate and the pull of the tendon are distributed evenly over the nail width.

Using the plastic tube makes the pull-out suture less bulky than buttons. Furthermore, the knot of the pull-out is done inside the tube (after being transformed into a gutter). These modifications make a less bulky construct and may minimize catching up with the clothing.<sup>8</sup>

Regular physical therapy sessions after surgery are an important aspect of treatment. We use an "active assisted mobilization" protocol for all patients.

This pull-out technique for fixation of zone one flexor tendon injury produced good results in experienced hands. We had no infection or permanent nail deformity in our series.

**Conflicting interests:** The authors declare no potential conflicts of interest with respect to the research, authorship, and/or publication of this article.

**Funding:** The authors received no financial support for the research, authorship, and/or publication of this article.

**Ethical approval:** The study received Institutional Review Board approval number: IRB00010835

**Details of informed consent:** All patients provided their written informed consent to participate in the study and to the anonymous use of their fingers photographs for publication.

Mohammadreza Azarpira MD<sup>1</sup>

Ghada Asmar MD<sup>1</sup>

Marc-Olivier Falcone MD<sup>1,2</sup>

1 Ramsay Générale de Santé, Capiro, Hôpital Privé Paul d'Egine, 4 avenue Marx Dormoy, Champigny-sur-Marne, France

2 Ramsay Générale de Santé, Capiro, Clinique Jouvenet, Jouvenet, Paris, France

## References

1. Chepla KJ, Goitz RJ, Fowler JR. Anatomy of the flexor digitorum profundus insertion. *J Hand Surg.* 2015; 40(2):240–4. doi: 10.1016/j.jhsa.2014.11.004.
2. Bunnell S. Primary repair of severed tendons the use of stainless steel wire. *Am J Surg.* 1940;47(2):502–16.
3. Kang N, Marsh D, Dewar D. The morbidity of the button-over-nail technique for zone 1 flexor tendon repairs. Should we still be using this technique? *J Hand Surg Eur Vol.* 2008;33(5):566–70. doi: 10.1177/1753193408090118.
4. Guinard D, Montanier F, Thomas D, Corcella D, Moutet F. The Mantero flexor tendon repair in zone 1. *J Hand Surg Br.* 1999; 24(2):148–51. doi: 10.1054/jhsb.1998.0173.
5. Bidwai ASC, Feldberg L. The button-over-nail technique for Zone I flexor tendon injuries. *Hand Surg.* 2012; 17(3):365–9. doi: 10.1142/S0218810412500323.
6. Tang JB, Giddins G. Why and how to report surgeons' level of expertise. *J Hand Surg Eur Vol.* 2016;41(4):365–6. doi: 10.1177/1753193416641590.
7. Moiemens NS, Elliot D. Primary flexor tendon repair in zone 1. *J Hand Surg Edinb Scotl.* 2000; 25(1):78–84. doi: 10.1054/jhsb.1999.0319.
8. Huq S, George S, Boyce DE. Zone 1 flexor tendon injuries: a review of the current treatment options for acute injuries. *J Plast Reconstr Aesthetic Surg JPRAS.* 2013; 66(8):1023–31. doi: 10.1016/j.bjps.2013.04.026.
9. Al-Qattan MM. Type 5 avulsion of the insertion of the flexor digitorum profundus tendon. *J Hand Surg Br.* 2001; 26(5):427–31. doi: 10.1054/jhsb.2001.0619.
10. McCallister WV, Ambrose HC, Katolik LI, Trumble TE. Comparison of pullout button versus suture anchor for zone I flexor tendon repair. *J Hand Surg Am.* 2006; 31(2):246–51. doi: 10.1016/j.jhsa.2005.10.020.
11. Rigó IZ, Røkkum M. Comparison of Transverse Intraosseous Loop Technique and Pull Out Suture for Reinsertion of the Flexor Digitorum Profundus tendon. A Retrospective Study. *J Hand Microsurg.* 2013;5(2):68–73. doi: 10.1007/s12593-013-0100-8.
12. Tempelaere C, Brun M, Doursounian L, Feron JM. Traumatic avulsion of the flexor digitorum profundus tendon. Jersey finger; a 29 cases report. *Hand Surg Rehabil.* 2017; 36(5):368–72. doi: 10.1016/j.hansur.2017.06.002.
13. Chu JY, Chen T, Awad HA, Elfar J, Hammert WC. Comparison of an all-inside suture technique with traditional pull-out suture and suture anchor repair techniques for flexor digitorum profundus attachment to bone. *J Hand Surg Am.* 2013; 38(6):1084–90. doi: 10.1016/j.jhsa.2013.02.015.
14. Matsuzaki H, Zaegel MA, Gelberman RH, Silva MJ. Effect of suture material and bone quality on the mechanical properties of zone I flexor tendon-bone reattachment with bone anchors. *J Hand Surg Am.* 2008; 33(5):709–17. doi: 10.1016/j.jhsa.2008.01.025.
15. Polfer EM, Sabino JM, Katz RD. Zone I Flexor Digitorum Profundus Repair: A Surgical Technique. *J Hand Surg Am.* 2019; 44(2): 164.e1-164.e5. doi: 10.1016/j.jhsa.2018.08.015.